



## ANATOMICAL AND SOME MORPHOMETRICAL FEATURES OF SMALL INTESTINE IN ADULT LOCAL SHEEP (*OVIS ARIES*) IN IRAQ

**Israa G. Hussein and Ahmed S. Al-A'araji**

Department of Anatomy, Embryology and Histology, Collage of Veterinary Medicine, Baghdad University, Iraq

Corresponding author: israa.g Hassan@yahoo.com

### Abstract

This study was conducted on 10 samples of small intestine for adult local sheep in Iraq. General gross description of intestine was done in situ immediately after animal slaughter whereas further study like morphometrical parameters related to the weight and length were completed in laboratory. The result proved that the intestine was pale pink to gray in color composed of three segments : the duodenum, the first part that start after the end of abomasum, jejunum, the middle and longest part and ileum, the terminal and shortest segment with no clear anatomical demarcation lines separating between them. These segments were situated at the right halve of abdomen attached to the right half abdominal wall and related to the dorsal aspect of the abdominal cavity. The result showed that the small intestine was nourished with blood vessels through two main Sources: the celiac trunk and the cranial mesenteric trunk; both of them were branched from common trunk named celiaco-mesenteric which arise from the aorta.

**Keywords:** Small intestine, Anatomical, morphometrical, sheep.

### Introduction

Food is the fundamental requirement that the animal body demands for growth and maintenance of the life through nutrients absorption Tarquinio (2012). It is impossible to use the food in its original form without changed by organs of digestive system that make it effortless absorbed in blood stream Nancy (2010). Small ruminants such as sheep are considered a significant provenance to output milk and meat even in inimical surroundings as well as hard situations and diseases resistant, so these animals have a great ability to create supplemental income especially in pauper rustic areas Gatenby (1982) & Huda (2017). The intestine does fundamental function in the digestion and absorption of different nutrients that animals consumed. Small intestine is the first site concerned with enzymatic breakdown of enzyme, in addition to absorption of carbohydrates, fatty acid, and amino acids AL-A'araji (2016). There is rarity of literatures on macroscopic and microscopic structure of this part of in the digestive tract excepting some researches have been achieved in some ruminants which is insufficient to established a good and obvious data base about the intestine Damron (2003). The current work was intended to investigate the anatomical and some morphometrical features of small intestine in adult local sheep.

### Materials and Methods

To achieve the objectives of this study, 10 samples of small intestines were used. All animals from which that the anatomical samples were taken were weighted before slaughter. All these parts of small intestine were observed, described in situ, photographed and collected instantly after animal slaying, then they were transmitted to laboratory in ice containers that make ability to fulfilment other aims of the study. Blood supply was injected with a mixture of three parts latex and two-part ammonium hydroxide colored with carmine stain in the common carotid artery.

### Results and Discussion

The present work revealed that the small intestine in adult local sheep was pale pink to gray in color, it is composed of highly vascularized three segments duodenum, the first part that start after the end of abomasum at pyloric region, jejunum, the middle and longest part and ileum, the terminal and shortest segment which attached to other group of organs called large intestine (Fig. 1, 2). It is important to mentioned that there are no anatomical demarcation lines to isolated these parts one from other (Fig. 2, 3). These findings were conformable with parish (2011) in his study on ruminants digestive system. All these segments were situated at the right halve of abdomen attached to the right half of the abdominal wall, largely covered with ribs, rumen and other digestive organs and related to the dorsal aspect of abdominal cavity (fig.4). An exact match between the results of this study and the results of that reported by Al-mansor in her study on indigenous Gazelle. The morphometric measurements of the three segments of small intestine are in table (1 & 2)

The deodenum was pale pink in color composed of five parts: cranial portion, cranial duodenal flexure, descending portion, caudal duodenal flexure, ascending duodenum and Duodenojejunal flexure. It originates with cranial portion at the level of 9<sup>th</sup>-10<sup>th</sup> rib near the pyloric region of true stomach (abomasum). The passageway of deodenum gives it ability to grasp the pancreas between its two limbs (ascending and descending parts) (Fig. 3). In the present work, the gross anatomical results on deodenum were compatible to a large extent with the results of many previous researches in different domestic animals Perez (2012), Christiane (2013), Gerard (2014) & Charly *et al.* (2015) After about 17 cm from the pylorus and exactly after the cranial duodenal flexure (*Flexura duodeni cranialis*) a straight duct opened in the start of descending part of duodenum to pass about 1 centimeter within the wall of duodenum as intra duodenal part or (intramural part) then it opened finally into the lumen with one or common papillae slightly to the left side (Fig. 5, 6). This distance between end

of abomasum and the papillae of duct was shorter than distance in study of Ajay and Chandra on intestine of goat who reported that the bile duct opened 26.5 to 30 cm away from the pylorus. The results of Jebri *et al.* proved that there were two papillae in first part of the duodenum (papilla duodeni major and papilla duodeni minor) in donkey's study. Both papillae were located near to each other with a distance less than 1 cm and very near to the *Ostium pyloricus*.

The jejunum was the second and longest segment of small intestine composed of high number of short series u-shaped mesenteric loops which act to prolonged it. The prevailing direction that these loops pass was are ventrally, caudally then dorsally toward the ileum and large intestine within the abdominal cavity. It starts after the end of duodenum at the duodenojejunal flexure and terminate at the junction with the ileum. The end of this segment of small intestine and start the next part is remarkable by an obvious fold called (ileocecal fold) and by thickening of the wall of the ileum (Fig.1, 2, 3, 4). Similar findings were reported in (2017) by Maruti in his study on sheep and goat. The present work shows that the length of the mesentery supported jejunum (mesojujenum) is much higher than that attached to the previous segment duodenum (meso dedonum), so the jejunum is appeared greatly mobile than deodenum (Fig. 7). These results were parallel to what mentioned by Maruti (2017) and bragulla (1991).

The ileum was the last segment of the small intestine appeared as straight short tubular organ connected to the jejunum shortly caudal to the head of cecum and directed toward the caudal end of the body. In fresh samples it's appeared as a light pink in color in the first two thirds while gray in color in the third last third. The ileum is Intermediate the position between spiral loops of ascending colon with centrifugal ansa from one side and the cecum with ileocecal fold from the other. The start of this organ which can be also recognized through an anatomical structure consist of peritoneal layer called ileocecal fold. The upper border of this fold is fixed to the ileum, contrary to its mesenteric side attachment side while its lower part reach to the ileocecal junction. Ileum ends at the other part of the digestive tract called large intestine, exactly at the cecum to opening at the ileoceco- colic orifice (Fig. 1, 2). A great similarity was present in the study of Constantinescu (2002) in goat and study of pachpande *et al.* in goat and sheep in which they mentioned that the ileum was the terminal segment of the small intestine. It passed cranially which was nearly straight and short to join the large intestine on the ventromedial

surface of the cecocolic junction. In the same context, Perez *et al.* (2014). Referred to the ileum in their study on deer and mentioned that it was attached to the caecum by the ileocecal fold which is opened into the large intestine through the ileal ostium.

The small intestine were nourished with blood through two main Sources: the celiac trunk and the cranial mesenteric trunk; both of them were branched from the common trunk named celiaco – mesenteric trunk which arise from the aorta in abdominal region (Fig. 8). This result was dissimilar to the result of Mohamed (2017) in his study on Barbados Black Belly sheep in which he found the cranial mesenteric artery originated separately from the ventral aspect of the abdominal aorta caudal to the origin of the celiac artery. In the present study the deodenum supplied with blood through the gastro-duodenal trunk which gives rise to the cranial pancreatico- duodenal artery that directed caudally to supply caudal and middle part of the duodenum to unite finally with caudal pancreatico-duodenal artery that originated from cranial mesenteric artery (Fig. 8). The blood vessels supplied the jejunum were branched directly from cranial mesenteric artery called (jejunal branches) which passed dorsally to jejunum and parallel to the centrifugal ansa (Fig. 9). The cecal branch arise also from cranial mesenteric artery to direct toward the end of cecum to nourish it by many small branches along the cecal course. Tiny obvious arteries arise from terminal portion of cecal artery supplying the first part of ileum (Fig. 10). The cecal artery have another branch directed dorsally named ileo-colic branch which nourished the last part of ileum near ileoceco colic orifice by two small arteries; as well as the ileo colic artery supplied the initial part of the colon (fig.11).Current findings as well as those obtained by Youssef (1991) in goat ascertained that the jejunal arteries were detached from the cranial aspect of the cranial mesenteric artery along its whole length. In addition to that the current investigation, corresponding with those of Youssef (1991) in goat, Wilkens and Munste (1981) in ruminants and Machado *et al.* (2002) in buffalo, in which they clarified that the cecal artery gave off cecal and antimesenteric ileal branches and continued as the antimesenteric ileal artery.

### Conclusions

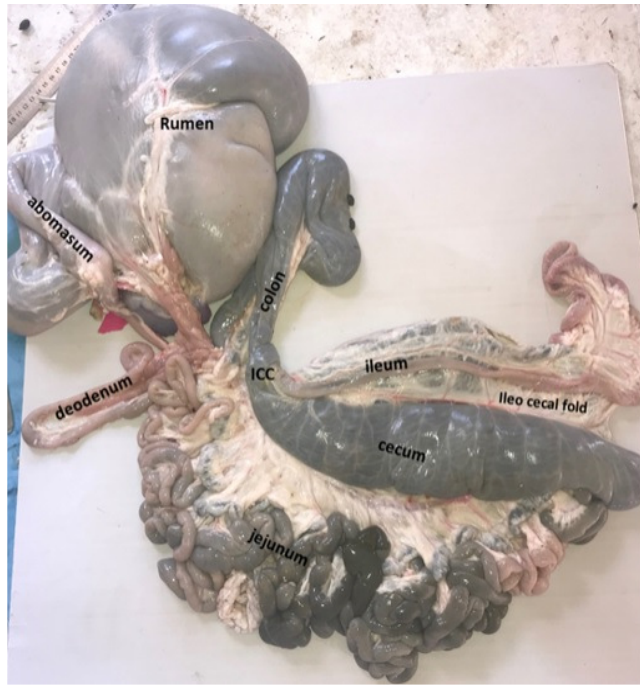- 1- No obvious differences in anatomical form between domestic sheep and other ruminants.
- 2- Morphological modifications of small intestine was desired in the sheep to performance its physiological role.

**Table 1:** Shows the weight of animal's body involved in this study, whole weight of small intestine, weight of each segment and the ratio of small intestine weight to body weight.

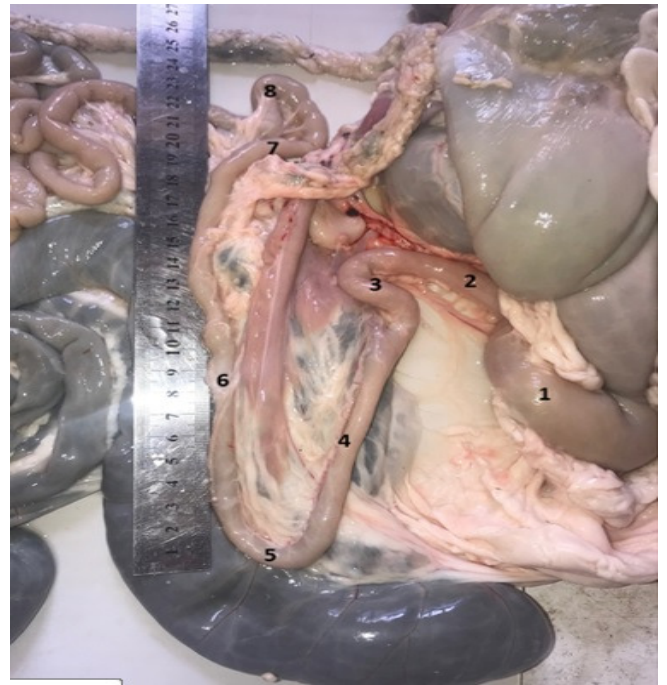Parameter	Range	Mean $\pm$ SE
Total Weight of animal's body	20- 29 Kg	23 $\pm$ 2.4
Weight of duodenum	22-39 gr	31 $\pm$ 4.2
Weight of jejunum	462-857 gr	674 $\pm$ 114
Weight of ileum	19- 28 gr	24 $\pm$ 2.5
Total weight of small intestine	503 - 924 gr	729 $\pm$ 121
Ratio of small intestine weight to body weight	2.515% - 4.045%	3.149 $\pm$ 0.5

**Table 2:** Shows the total length of small intestine, length of duodenum, jejunum, ileum, and the ratio of length each segment to the total length of intestine.

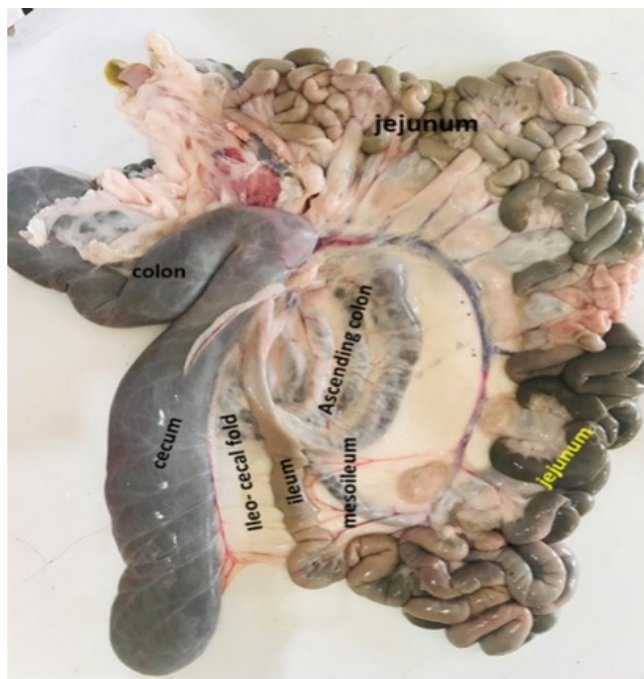Parameter	Range	Mean ± SE
length of duodenum	52 – 61 cm	57 ± 2.6
length of jejunum	1143 – 1164 cm	1155 ± 6.1
length of ileum	29 – 36 cm	33 ± 2.0
Total length of small intestine	1224 – 1261 cm	1242 ± 10.7
Ratio of duodenal length to small intestine length	4.248 – 4.837 %	4.583 ± 0.2
Ratio of jejunal length to small intestine length	92.307 % - 93.382 %	92.763 ± 0.3
Ratio of ileal length to small intestine length	2.369 – 2.868 %	2.654 ± 0.1



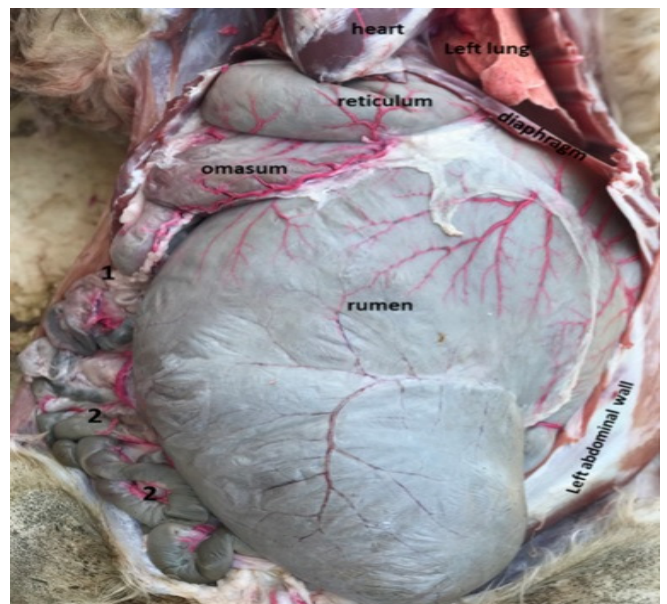
**Fig. 1:** The small intestine in adult local sheep appeared pale pink to gray in color composed of three segments: deodenum, jejunum and ileum.



**Fig. 3:** Course of deodenum with its parts.1: abomasum2: Cranial portion3: Cranial duodenal flexure 4: Descending portion.5: Caudal duodenal flexure 6: Ascending duodenum 7: Deodenojejunal flexure. 8: jejunum

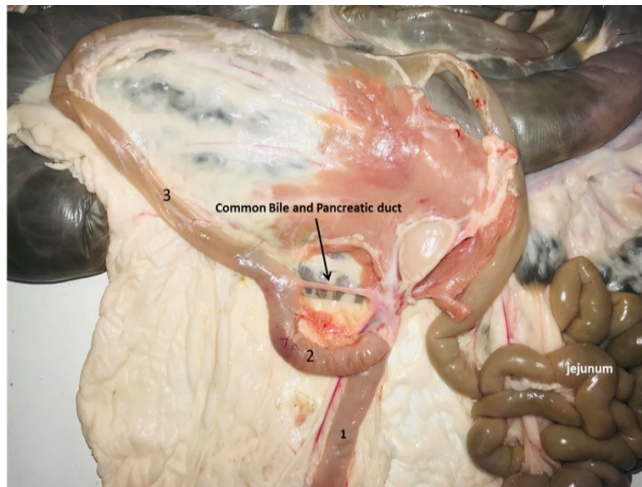

**Fig. 2:** Gross section in small intestine of adult local sheep. Jejunum the middle and longest part. Ileum the terminal portion which attached to cecum.

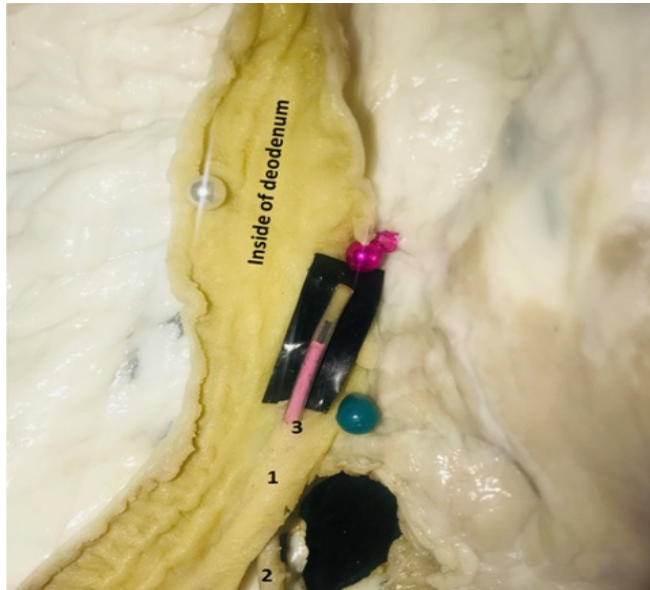

**Fig. 4:** Position of the small intestine in abdominal cavity which attached to the right abdominal wall. The jejunum and small segment of deodenum are the only parts of the intestine that are exposed when the abdominal cavity opened in midline.

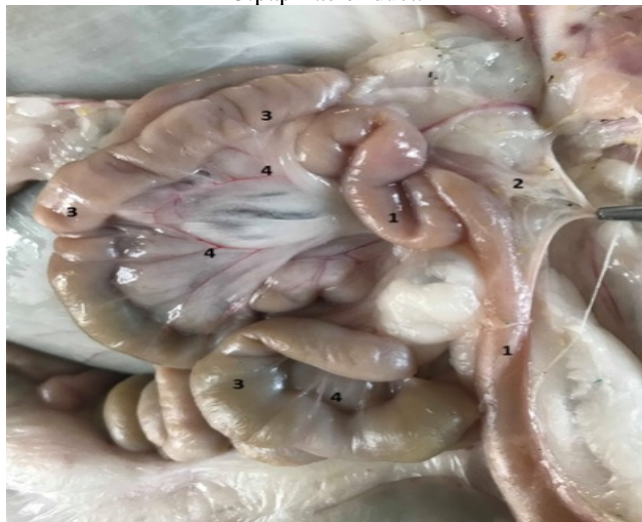



**Fig. 5:** Common bile and pancreatic duct which opened in deodenum at the cranial duodenal flexure. 1: deodenum 2: cranialduodenal flexure 3: Descending portion of deodenum.



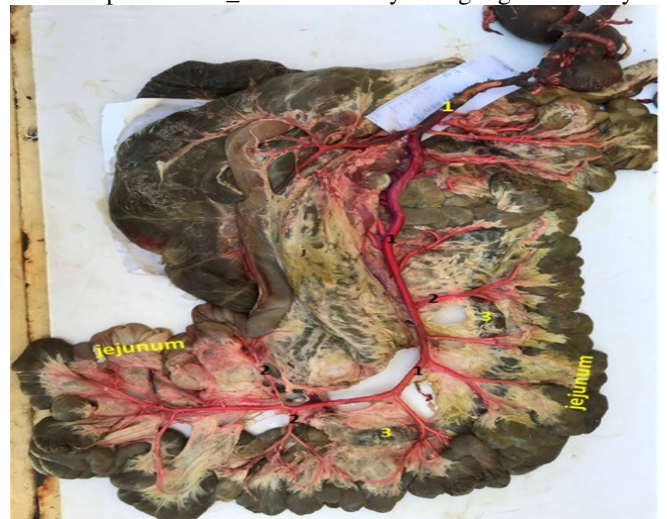**Fig. 6:** Papillae of common bile and pancreatic duct inside the deodenum. 1: intramural part 2: entrance of duct 3: papillae of duct.



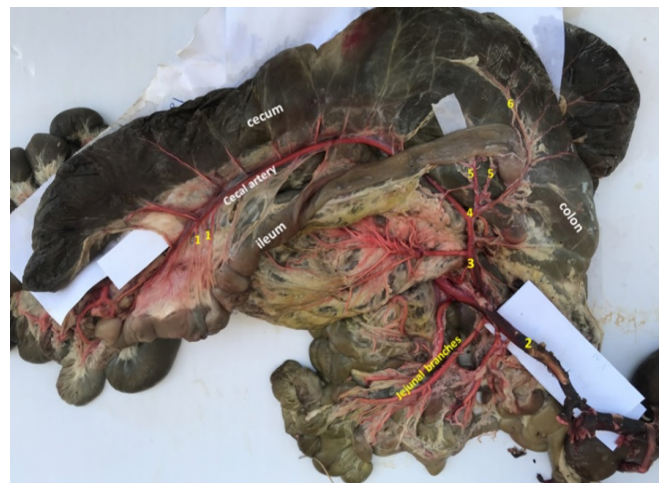**Fig. 7:** Mesojejunum which appeared longer than mesodeodenum in order to give jejunum exceptional level of mobility. 1: deodenum 2: mesodeodenum 3: jejunum 4. mesojejunum



**Fig. 8:** Blood supply branching of small intestine. 1: abdominal aorta 2: celiaco – mesenteric trunk 3: celiac trunk 4: cranial mesenteric artery 5: splenic artery 6: hepato-gastric trunk 7: left gastric artery 8: hepatic artery 9: cystic artery 10: gall bladder 11: gastro- duodenal trunk 12: right gastric epiploic artery 13:cranial pancreaticoduodenal artery 14: caudal pancreatico\_ duodenal artery 15:right gastric artery

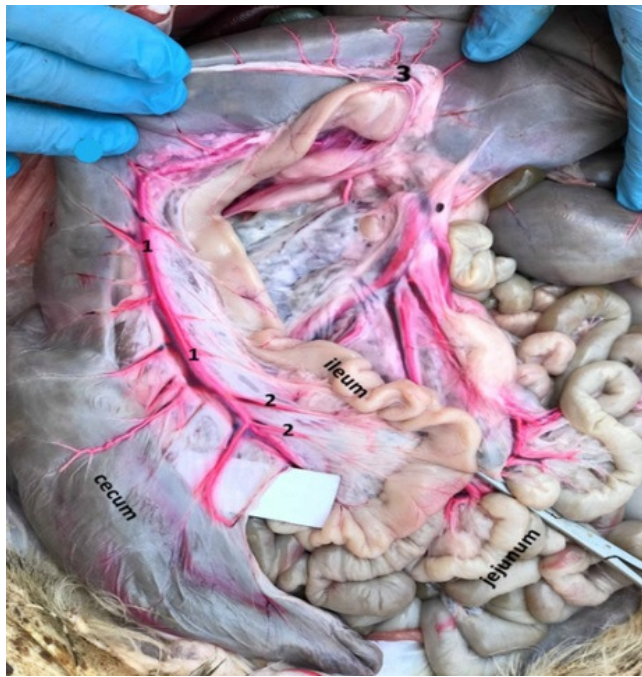

**Fig. 9:** Branching of cranial mesenteric artery in supplying jejunum with blood. 1: cranialmesentericartery 2: jejunalbranches 3: centrifugal ansa.



**Fig. 10:** Branching of cecal artery.1: ileal branches 2: cranial mesenteric artery 3: cecal artery 4: ileo colic artery5: ileal arteries 6:colic artery





**Fig. 11:** Cecal artery and its branches to supplying the ileum. 1: cecal artery 2: ileal arteries or (branches) 3: ileocecolic orifice.

### References

- Ajay, P. and Chandra, G. (2000). Gross anatomical studies on intestine of goat, *Ind. J. Vet. Anat.*, 12(1): 23-26.
- AL-A'araji, A.S. and AL-Kafagy, S.M. (2016). A comparative anatomical, histological and histochemical study of small intestine in Kestrel (*Falco tinnunculus*) and white eared bulbul (*Picnonotus leucotis*) according to their food type. *The Iraqi Journal of Veterinary Medicine*, 40(2): 36-41.
- Al-Mansor, N.A.S. (2018). Anatomical and Histological Study of Small Intestine in Adult Male Indigenous Gazelle (*Gazella subgutturosa*). MSc. Thesis. Anatomy and Histology department. collage of Veterinary Medicine. Baghdad University.
- Bragulla, H. (1991). Die Hinfallige Hufkapsel (Capsula unguale decidua) of Pferde-fetus und neugeborenen Fohlens. *Anat. Histol. Embryol.*; 20: 66-74.
- Charly, P.; Minh, H.; Roman, H. and Vladimir, J. (2015). *Veterinary Clinics of North America Exotic Animal Practice*, 18(3): 369-400.
- Christiane, S.; Elise, R. and Reto, N. (2013). Gastrointestinal endoscopy in the cat: Equipment, techniques and normal findings. *Journal of Feline Medicine and Surgery*, 15: 977-991.
- Ciccocioppo, R.; Sabatino, A.D.; Parroni, R.; Muz, P.; Alò, S.D.; Ventura, T.; Pistoia, M.A.; Cifone, M.G. and Corazza, G.R. (2015). Increased enterocyte apoptosis and Fas-Fas Ligand System in celiac disease. *Am. J. Clin. Pathol.*; 115: 494-503.
- Constantinescu, G.M. (2002). *Clinical Anatomy for Small Animal I*. Ames: Iowa State Press.
- Damron, S.W. (2003). *Introduction to Animal Science*. 2nd. editions. Prentice Hall Co. U.S.A. 95-111.
- Gatenby, R.M. and Trail, J.C.M. (1982). *Small ruminant breed productivity Africa*. International Livestock Centre for Africa, Addis Ababa, Ethiopia.
- Gerard, T. (2014). *Principles of Anatomy & Physiology*. USA: Wiley. P: 913.
- Huda Shadhan Awadha Eman Fasial Abdall Hassan (2017). Detection of cholecystikinin and glucagon like peptide in small intestine of Awassi sheep. *AL-Qadisiyah Journal of Vet. Med. Sci.*, 16(1).
- Jerbi, H.; Rejeb, A.; Erdogan, S. and Perez, W. (2014). Anatomical and morphometric study of gastrointestinal tract of donkey (*Equus africanus asinus*). *J. Morphol. Sci.*, 31(1): 18-22.
- Machado, M.R.F.; Miglino, M.A.; Didio, L.J.A.; Honsho, D. and Borges, E.M.C. (2002). The arterial supply of buffalo intestines (*Bubalus Bubalis*). *Buffalo Journal*, 18(2): 249-256.
- Maruti, G.M. (2017). Comparative gross anatomical and histomorphological studies on small intestine in sheep (*Ovis aries*) and goat (*Capra hircus*). M.Sc. Thesis. veterinary anatomy and histology department. Krantisinh Nana Patil College of veterinary science. Maharashtra Animal and Fishery Sciences University, Nagpur.
- Mohamed, R. (2017). Anatomical studies on the cranial and caudal mesenteric arteries of the Barbados Black Belly sheep. *J. Morphol. Sci.*, 34(2): 93-97.
- Nancy, D.B. (2010). *The digestive system*. University of maine. School of social work, Pp:1-9.
- Pachpande, A.M.; Dhande, P.L.; Lambate, S.B.; Ghule, P.M.; Yadav, G.B. and Gaikwad, S.A. (2011). Gross anatomical and Biometrical observation on small intestine of goat, *Ind. J. Vet. Anat.* 23(2): 49-55.
- Parish, J. (2011). *Ruminant Digestive Anatomy and Function*. Beef Production Strategies.
- Perez, W. and Vazquez, N. (2012). Gross anatomy of the gastrointestinal tract in the Brown Brocket deer (*Mazama gouazoubira*). *J. Morphol. Sci.*, 29(3): 148-150.
- Perez, W.; Erdogan, S. and Ungerfeld, R. (2014). Anatomical Study of the Gastrointestinal Tract in Free-living Axis Deer (*Axis axis*). Blackwell Verlag GmbH, *Anat. Histol. Embryol*
- Tarquinio, D.; Motil, K.; Hou, W.L. and Percy, A.K. (2012). Growth failure in Rett syndrome: Specific growth references. *Neurology*, 79:1653-1661.
- Wilkins, H. and Munster, W. (1981). *The circulatory system*. In Nickel, A., Schumer, R. and Seiferle, E. *The anatomy of the domestic animals*. Hamburg: Wright Verlag Paul Parey, 3: 159-268.
- Youssef, A. (1991). Some anatomical studies on the coeliac, cranial mesenteric and caudal mesenteric arteries of goat. M.sc. Thesis. Benha: Faculty of Veterinary Medicine, Zagazig University.